



<http://dx.doi.org/>

<http://www.higieneanimal.ufc.br>

Review

Medicina Veterinária

Evidences in the treatment of feline leishmaniasis: literature review

Evidências no tratamento da leishmaniose felina: revisão de literatura

Camila Rodrigues de França¹, Sara Barbosa Costa², Hilda Lara Costa Cardoso³, Luana Cortez Passos⁴, Rebecca Carolina Oliveira da Costa⁵, Kamilla Maria Teixeira Asevedo⁶, Neilton Monteiro Pascoal Filho⁷, Tiago Cunha Ferreira⁸

Abstract: Leishmaniasis is a zoonotic disease caused by protozoa of the genus *Leishmania*. While dogs are considered the primary reservoir, feline leishmaniasis (FL) has been increasingly documented in endemic regions. Therapeutic and prophylactic options for FL remain notably limited, posing significant challenges for disease management in feline patients. This literature review aims to synthesize the existing therapeutic strategies for FL to support veterinarians in clinical decision-making. It is concluded that the available evidence on FL treatment is limited, highlighting the need for further clinical trials to establish the efficacy and safety of existing pharmacological interventions.

Keywords: Zoonosis. LFel. Therapeutics.

Resumo: A leishmaniose é uma zoonose causada por protozoários pertencentes ao gênero *Leishmania*. O cão é considerado o principal reservatório da doença, entretanto a leishmaniose felina (LFel) vem sendo progressivamente reportada em áreas endêmicas. Tanto as opções terapêuticas quanto as profiláticas para LFel são restritas para a espécie, tornando o manejo da doença ainda mais desafiador no paciente felino. Esta revisão de literatura objetiva sintetizar as estratégias terapêuticas disponíveis para LFel a fim de auxiliar os médicos veterinários em suas condutas clínicas. Conclui-se que as evidências disponíveis relativas à terapia da LFel são limitadas e são necessários mais ensaios clínicos para determinar a eficácia e a segurança das drogas conhecidas.

Palavras-chave: Zoonose. LFel. Terapêutica.

<http://dx.doi.org/10.5935/1981-2965.20250005>

Autor para correspondência. E-mail: luanacortezp@gmail.com

Recebido em 5.5.2025. Aceito em 30.16.2025

Graduanda em Medicina Veterinária pela Universidade Estadual do Ceará (UECE). Email: mila.new.rf@gmail.com¹

Graduanda em Medicina Veterinária pela Universidade Estadual do Ceará (UECE). Email: sara_barbosa_costa@hotmail.com²

Graduanda em Medicina Veterinária pela Universidade Estadual do Ceará (UECE). Email:

hildalaracostacardoso@gmail.com³

Graduanda em Medicina Veterinária pela Universidade Estadual do Ceará (UECE). Email:

luanacortezp@gmail.com⁴

Graduanda em Medicina Veterinária pela Universidade Estadual do Ceará (UECE). Email:

rebeccacarolina520@gmail.com⁵

Graduanda em Medicina Veterinária pela Universidade Estadual do Ceará (UECE). Email:

kamilla.teixeira@aluno.uece.br⁶

Docente da Faculdade de Veterinária da Universidade Estadual do Ceará (UECE). E-mail:

neilton.monteiro@uece.br⁷

Docente da Faculdade de Veterinária da Universidade Estadual do Ceará (UECE). E-mail:

tiago.cunha@uece.br⁸

INTRODUCTION

Leishmaniasis is a vector-borne zoonosis transmitted by phlebotomine sandflies and caused by intracellular protozoa belonging to the *Leishmania* genus (Abramo et al., 2021). In humans, this disease is classified among the most significant neglected tropical diseases worldwide and holds substantial relevance in the context of public health, particularly in countries located in endemic regions, such as Brazil (Brianti et al., 2017).

The dog is considered the primary reservoir of the disease (Lopes-Neto et al., 2015). However, feline leishmaniasis (FL), caused by *Leishmania infantum*, has been increasingly reported in endemic areas for visceral leishmaniasis (Pennisi & Persichetti, 2018). The role of cats in the epidemiology of the disease appears to be that of a reservoir rather than merely accidental hosts, contrary to initial beliefs (SOARES et al., 2016).

The increasing reports of feline leishmaniasis (FL) have been correlated not only with the advancement of diagnostic techniques available in feline medicine but also possibly with the adaptation of the protozoan to new hosts. Additionally, changes in the feeding habits of phlebotomine sandflies may be influencing this trend, potentially due to the widespread use of repellent agents as a preventive measure in dogs (Abramo et al., 2021).

Cats infected with feline leishmaniasis (FL) are predominantly asymptomatic or present with subclinical disease. When clinical manifestations occur, they can include a wide range of signs; however, cutaneous or mucocutaneous lesions and lymphadenomegaly are the most common clinical signs of the disease (Abramo et al., 2021). A smaller proportion of affected animals exhibit systemic signs, which may include uveitis, blepharitis, conjunctivitis,

chronic gingivostomatitis, weight loss, hyporexia, dehydration, lethargy, cachexia, mucosal pallor, hepatomegaly, jaundice, fever, diarrhea, vomiting, splenomegaly, polyuria, polydipsia, sneezing, chronic nasal discharge, dyspnea, abortion, and hypothermia (PENNISI et al., 2015).

The dermatological manifestations of feline leishmaniasis (FL) primarily include nodules and ulcerations, which can be distributed in generalized or localized patterns and may appear symmetrically or asymmetrically (Figure 1).

Cutaneous and mucocutaneous nodules vary in size and are most commonly located on the head, including

the eyelids, nose, and lips, as well as on the distal parts of the limbs. Ulcerations can be diffuse and superficial or focal and deep, with the most common locations being the same as those observed for nodular lesions. Exfoliative dermatitis is a rare presentation of FL (PENNISI et al., 2015).

Regarding therapeutic and prophylactic options for feline leishmaniasis (FL), they are considerably more limited than those available for canine leishmaniasis (CL), making disease management even more challenging for clinicians when it occurs in feline patients (BRIANTI et al., 2017; TORRES et al., 2022).

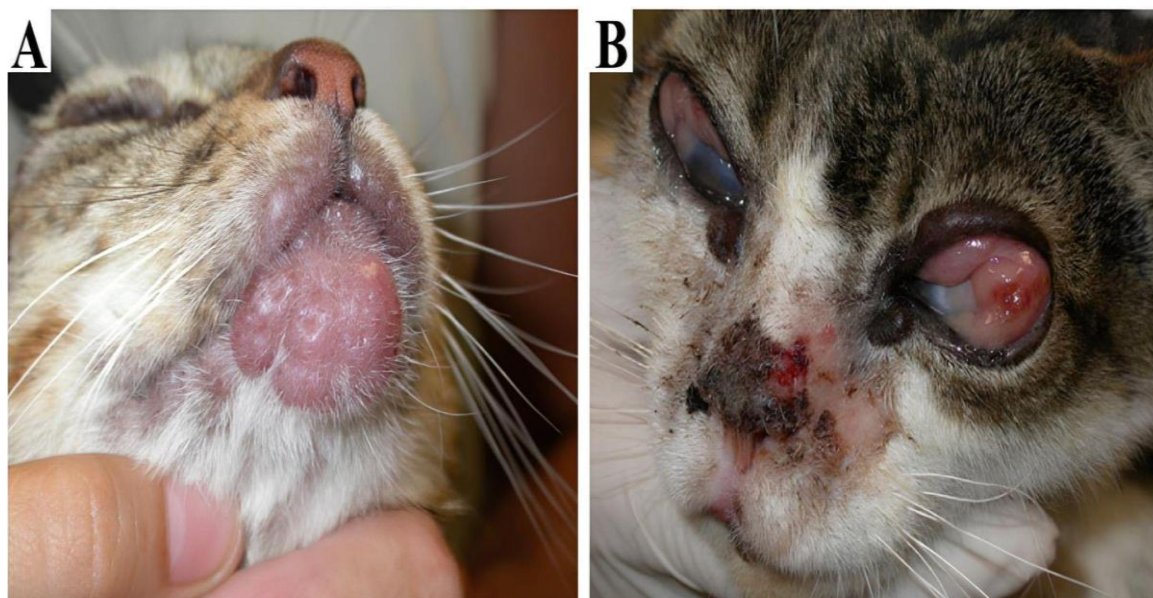


Figure 1. Clinical presentation of Feline Leishmaniasis. (A) Papules on the upper lip region and plaques on the chin. (B) Papules on the eyelid region, corneal edema, chemosis, ulcers, and crusts on the nasal bridge and planum. Source: Adapted from Galego et al., 2020.

Feline leishmaniasis is shifting from being an extremely rare disease to an

increasingly frequent condition encountered in veterinary clinics in

endemic regions. Therefore, this literature review aims to synthesize the available therapeutic strategies for managing this disease, providing information that can assist veterinary professionals in their clinical decision-making.

THERAPEUTIC STRATEGIES

The therapeutic strategies for FL include allopurinol (Pennisi et al., 2015; Pennisi & Persichetti, 2018; Napoli et al., 2022; Tiozzo et al., 2023), N-

methylglucamine antimoniate (Pennisi et al., 2015; Basso et al., 2016; Soares et al., 2016; Pennisi & Persichetti, 2018; Gallego et al., 2020; Pereira & Maia, 2021), domperidone (Travi & Miró, 2018; Abramo et al., 2021), miltefosine (Leal et al., 2018; Abramo et al., 2021), marbofloxacin (Libert et al., 2012; Pineda et al., 2017; Hopke et al., 2021), and pentamidine (SOARES et al., 2016). Table 1.

Table 1. Drug data: dosage and administration frequency for the treatment of Feline Leishmaniasis.

THERAPY	DOSE	FREQUENCY	REFERENCE
Allopurinol	10 mg/kg or 20 mg/kg PO	S.I.D. ou B.I.D.	Pennisi <i>et al.</i> , 2015
Allopurinol + Domperidone	10 mg/kg PO + 0.5 mg/kg PO	B.I.D. S.I.D.	Abramo <i>et al.</i> , 2021; Pennisi & Persichetti, 2018
Allopurinol + N- methylglucamine antimoniate	10 mg/kg PO + 50 mg/kg SC	B.I.D. S.I.D.	Basso <i>et al.</i> , 2016
N-methylglucamine antimoniate	20-50 mg/kg SC 175mg/cat IM	S.I.D. Every other day	Pennisi <i>et al.</i> , 2015
N-methylglucamine antimoniate + Ketoconazole	5 mg/kg SC + 10 mg/kg PO	S.I.D. S.I.D.	Soares <i>et al.</i> , 2016
Domperidone	0.5 mg/kg PO	S.I.D.	Abramo <i>et al.</i> , 2021; Schäfer <i>et al.</i> , 2023
Miltefosine	2mg/kg PO	S.I.D.	Pennisi & Persichetti, 2018; Abramo <i>et al.</i> , 2021; Gallego <i>et al.</i> , 2020
Marbofloxacin	3.5 mg/kg PO	S.I.D.	Hopke <i>et al.</i> , 2021
Metronidazole + Spiramycin	25 mg/kg PO + 150.000 UI/kg PO	S.I.D. S.I.D.	Pennisi <i>et al.</i> , 2015
Pentamidine	4 mg/kg IM	Not specified	Pennisi <i>et al.</i> , 2015

PO: Oral administration; **SC:** Subcutaneous administration; **IM:** Intramuscular administration.

While some of these treatments were administered as monotherapy, others were used in combination, highlighting the variability in therapeutic approaches for FL. The use of combination therapies suggests an attempt to enhance treatment efficacy, considering the challenges associated with managing this disease in feline patients.

Allopurinol

Allopurinol is the primary drug used in the treatment of feline leishmaniasis (FL); however, limited information is available regarding its safety margin and effects in feline species. Nevertheless, clinical improvement has been observed in most treated animals, including some that tested positive for feline immunodeficiency virus (FIV), within a few weeks or months of treatment (PENNISI et al., 2015). The recommended dosage is 10 mg/kg every 12 hours or 20 mg/kg every 24 hours, administered orally, with the possibility of reducing the dose to 5 mg/kg every 12 hours in case of adverse effects (PENNISI et al., 2015). Although side effects have been reported only in a few cases, one of the main challenges of this therapy is the oral administration in cats, which may be poorly accepted by both the patient and the owner, complicating long-term treatment and often

leading to therapy discontinuation (NAPOLI et al., 2022).

In some cases of long-term allopurinol use, symptoms reappeared after treatment discontinuation, indicating that the infection persisted and continued to progress. Additionally, an increase in liver enzyme levels was observed in one cat, leading to a dose reduction (PENNISI et al., 2015). Another concern is the potential nephrotoxicity (acute kidney injury) associated with the medication, which was reported in two cases. In both instances, the condition improved after dose reduction and supportive treatment, suggesting a possible link between renal injury and allopurinol use (TIOZZO et al., 2023). For this reason, cats with pre-existing renal disease should be closely monitored throughout the treatment (PENNISI & PERSISCHETTI, 2018). Despite the potential side effects observed in some cases, the use of allopurinol as a therapeutic option for feline leishmaniasis (FL) has provided a good survival period for treated patients (NAPOLI et al., 2022).

N-methylglucamine antimoniate

N-methylglucamine antimoniate is the second most commonly reported drug for the treatment of feline leishmaniasis

(FL) (PENNISI et al., 2015). However, it is important to highlight that in Brazil, according to the Ministry of Health, this drug is prohibited for the treatment of leishmaniasis in dogs and, consequently, in cats, as it is not registered with the Ministry of Agriculture and Livestock (MAPA). Thus, its use in veterinary medicine is restricted within the country (Brasil, 2008).

In the available reports, the few cats treated with N-methylglucamine antimoniate achieved clinical cure. The treatment protocols used varied, including doses of 20 to 50 mg/kg administered subcutaneously every 24 hours for 20 to 30 days or 175 mg/cat administered intramuscularly every 48 hours for 55 days. Although remission was achieved in these cases, it is important to note that long-term follow-up was not conducted to assess potential recurrences of clinical manifestations (PENNISI et al., 2015).

One patient treated with 300 mg/cat of antimoniate administered subcutaneously every 24 hours also achieved clinical cure; however, four months after treatment, the cat developed nephropathy (GALEGO et al., 2020). Acute kidney injury has also been reported as an adverse effect associated with the use of this drug in cats (LEAL et al., 2018).

Domperidone

Domperidone, a dopamine D2 receptor antagonist, is widely recognized as an immunotherapy drug in dogs for preventing or managing *L. infantum* infection due to its ability to modulate cellular immunity. This action includes reducing the risk of seronegative individuals developing active infection, as well as promoting clinical improvement and controlling disease progression in already established cases (TRAVI & MIRÓ, 2018; ABRAMO et al., 2021).

Despite its therapeutic benefits, domperidone presents a potential risk of cardiotoxicity, particularly when administered concurrently with drugs that inhibit cytochrome P450 liver enzymes or prolong the QT interval. These interactions can increase plasma drug concentrations, thereby elevating the risk of adverse effects. A thorough assessment of variables such as age, breed, and hormonal status—factors that influence hepatic metabolic capacity—is essential to minimize risks and optimize therapeutic outcomes (TRAVI & MIRÓ, 2018).

Although specific studies on the efficacy of domperidone in managing FL are lacking, its immunomodulatory properties, combined with observed results

in other species, suggest a therapeutic potential worth exploring in cats. The treatment protocol previously used in a feline case consisted of 0.5 mg/kg administered orally once daily in two cycles of 28 days (SCHÄFER et al., 2023). Further investigation of this drug in felines could provide new perspectives for disease control in this species (ABRAMO et al., 2021).

Miltefosine

Miltefosine is a leishmanicidal drug commonly used in dogs for the treatment of leishmaniasis, acting against amastigote forms in the bloodstream (FILHO et al., 2008). Some authors have reported its use in cats, not only for the treatment of leishmaniasis but also for other fungal infections, such as sporotrichosis (LEAL et al., 2018; ABRAMO et al., 2021; PAULA et al., 2023). Abramo et al. (2021) investigated the combined use of miltefosine with meglumine antimoniate and allopurinol, while Leal et al. (2018) described miltefosine as a potential alternative to meglumine antimoniate in combination with allopurinol, highlighting its successful outcome in an azotemic cat, with fewer observed side effects.

However, it is important to consider that the oral formulation of miltefosine licensed for the treatment of canine

leishmaniasis (Milteforan®) contains propylene glycol, which can lead to the formation of Heinz bodies and reduce the lifespan of feline erythrocytes (PENNISI & PERSISCHETTI, 2018). Additionally, studies have reported adverse effects associated with miltefosine use, including hyporexia, sialorrhea, vomiting, and diarrhea, which can result in weight loss (PAULA et al., 2023). Despite these findings, a study investigating the use of miltefosine for the treatment of sporotrichosis in cats (Silva et al., 2018) did not observe any side effects related to the presence of propylene glycol in treated animals, even when administered for periods ranging from 3 to 45 days.

Marbofloxacin

Marbofloxacin (MBF), a third-generation fluoroquinolone, has emerged as a promising therapeutic alternative for the treatment of leishmaniasis, demonstrating efficacy and safety in cases of infection in nephropathic dogs. Studies indicate clinical improvement in more than 60% of treated dogs, with adverse effects generally being mild and limited to the gastrointestinal tract, such as diarrhea, which was observed in only a small percentage of animals (PINEDA et al., 2017).

However, reports on the use of MBF for the treatment of leishmaniasis in cats

remain scarce in the literature. According to Hopke et al. (2021), a cat positive for *Leishmania mexicana*, presenting with lesions on the ear and tarsus, was treated with MBF (3.5 mg/kg orally every 24 hours) for 40 days but did not show significant improvement, as the dermatological condition persisted even after treatment.

Nevertheless, the potential antileishmanial activity of marbofloxacin (MBF) should not be disregarded. As demonstrated by Libert et al. (2012), the combination of marbofloxacin (2 mg/kg orally every 24 hours for 28 days) and allopurinol (30 mg/kg orally every 24 hours for three months) led to clinical remission of leishmaniasis in a lioness, confirming its efficacy in treatment. This result suggests that MBF could also be a viable alternative for cats. Therefore, further studies on this drug should be encouraged to expand the therapeutic options available for feline leishmaniasis.

Pentamidine

Pentamidine is an aromatic diamine that has been used as a second-line drug for the treatment of human visceral leishmaniasis, particularly in cases of resistance to antimonial therapy. Intramuscular administration at the same dosage used for dogs (4 mg/kg) in a feline

patient resulted in clinical remission of symptoms. However, reports on its use for FL are significantly scarcer compared to other drugs, making its application more restricted (Soares et al., 2016).

Combined therapy

Combined therapy is a frequently used alternative to monotherapy in the treatment of feline leishmaniasis (FL). Among the most commonly reported combinations, allopurinol (10 mg/kg every 12 hours) in conjunction with N-methylglucamine antimoniate (50 mg/kg every 24 hours) is frequently mentioned, yielding satisfactory results in the remission of dermatological lesions (Figure 1) (BASSO et al., 2016; PEREIRA et al., 2021). However, this combination has also been cited as a potential inducer of acute kidney injury and is therefore not recommended for cats with pre-existing renal conditions (LEAL et al., 2018).

Despite the lack of extensive studies, the combination of allopurinol (10 mg/kg every 12 hours) and domperidone (0.5 mg every 24 hours) has also been considered promising in feline cases (ABRAMO et al., 2021; PENNISI & PERSISCHETTI, 2018). Another reported combination involves the use of meglumine antimoniate (5 mg/kg subcutaneously) with ketoconazole (10 mg/kg), both

administered every 24 hours (Pereira et al., 2021). Additionally, the combination of metronidazole (25 mg/kg) with spiramycin (150,000 IU/kg), both given orally every 24 hours, has also been documented (PENNISI et al., 2015).

Due to the absence of controlled clinical trials to assess the efficacy and safety of therapeutic strategies for feline

leishmaniasis, treatment is largely empirical, based on knowledge derived from canine treatment protocols. As a result, it is essential to perform complementary diagnostic tests and conduct regular follow-ups to monitor patient responses to therapy, including the potential emergence of adverse effects (PENNISI & PERSISCHETTI, 2018).

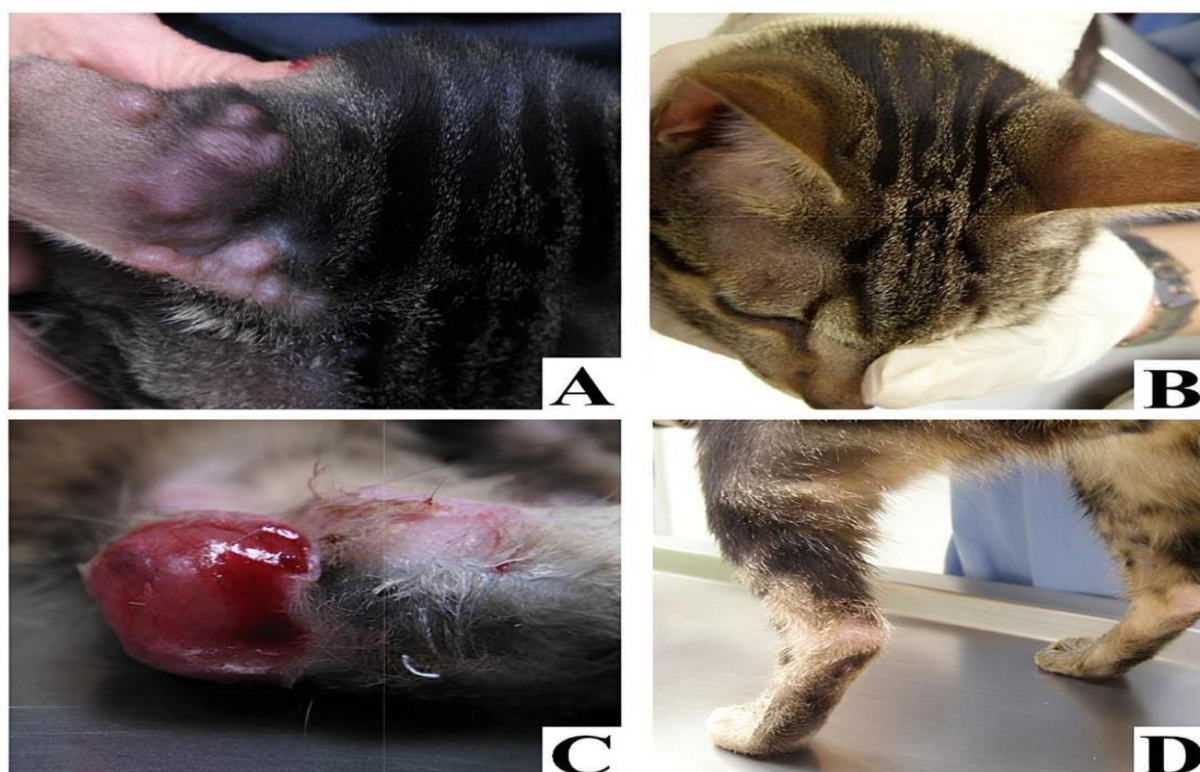


Figure 2. Evolution of Feline Leishmaniasis. (A) Multiple coalescent nodular skin lesions located on the head region. (B) Complete remission observed after 45 days of treatment. (C) Ulcerative dermatitis with raised margins on the hind limbs. (D) Total healing following surgical intervention. **Source:** Adapted from Basso et al., 2016.

Final considerations

The treatment of feline leishmaniasis primarily relies on meglumine antimoniate and allopurinol; however, in Brazil, the use of meglumine

antimoniate in animals is not authorized, limiting one of the most commonly reported therapeutic options. Current evidence on FL treatment remains scarce, underscoring the need for clinical trials to assess the efficacy

and safety of existing drugs and explore promising alternatives. Marbofloxacin, for instance, has shown positive outcomes in dogs and lions, but its effectiveness in cats remains unverified. Given these limitations, continuous monitoring of treated patients is essential to ensure therapeutic success and minimize potential adverse effects.

References

- ABRAMO, F.; ALBANESE, F.; GATTUSO, S.; RANDONE, A.; FILECCIA, I.; DEDOLA, C.; IBBA, F.; OTTAIANO, P.; BRIANTI, E. Skin lesions in feline leishmaniosis: A systematic review. **Pathogens**, v.10, n.4, p.472-489, 2021. DOI: 10.3390/pathogens10040472.
- BASSO, J. A.; MARQUES, C.; SANTOS, M.; DUARTE, A.; PISSARRA, H.; CARREIRA, L. M.; GOMES, L.; VALÉRIO-BOLAS, A.; TAVARES, L.; SANTOS-GOMES, G.; FONSECA, I. P. Successful treatment of feline leishmaniosis using a combination of allopurinol and N-methylglucamine antimoniate. **Journal of Feline Medicine and Surgery Open Reports**, v.2, n.1, p.1-7, 2016. DOI: 10.1177/2055116916630002.
- BRASIL. Ministério da Saúde. Gabinete do Ministro. Portaria nº 1.426, de 11 de julho de 2008. Brasília, 2008.
- BRIANTI, E.; FALSONE, L.; NAPOLI, E.; GAGLIO, G.; GIANETTO, S.; PENNISI, M. G.; PRIOLO, V.; LATROFA, M. S.; TARALLO, V. D.; BASANO, F. B.; NAZZARI, R.; DEUSTER, K.; POLIMEIER, M.; GULOTTA, L.; COLELLA, V.; TORRES, F. D.; CAPELLI, G.; OTRANTO, D. Prevention of feline leishmaniosis with an imidacloprid 10%/flumethrin 4.5% polymer matrix collar. **Parasites & Vectors**, v.10, n.1, p.334-342, 2017. DOI: 10.1186/s13071-017-2258-6.
- FILHO, A. V. C.; LUCAS, Í. C.; SAMPAIO, R. N. R. Estudo comparativo entre miltefosina oral e antimonio de N-metil glucamina parenteral no tratamento da leishmaniose experimental causada por *Leishmania (Leishmania) amazonensis*. **Revista da Sociedade Brasileira de Medicina Tropical**, v.41, n.4, p.424-427, 2008. DOI: 10.1590/S0037-86822008000400022.
- GALLEGO, A. F.; BERNABE, L. F.; DALMAU, A.; ESTEBAN-SALTIVERE, D.; FONT, A.; LEIVA, M.; ORTUÑEZ-NAVARRO, A.; PEÑA, T. M.; TABR, T. D.; REAL-SAMPIETRO, L.; SALÓ, F.; LLORET, A.; BARDAGÍ, M. Feline leishmaniosis: diagnosis, treatment and outcome in 16 cats. **Journal of Feline Medicine and Surgery**, v.22, n.10, p.993-1007, 2020. DOI: 10.1177/1098612X20902865.
- HOPKE, K.; MEYERS, A.; AUCLAND, L.; HAMER, S.; FLORIN, D.; DIESEL, A.; PATTERSON, A. *Leishmania mexicana* in a central Texas cat: clinical presentation, molecular identification, sandfly vector collection and novel management. **Journal of Feline Medicine and Surgery Open Reports**, v.7, n.1, p.1-6, 2021. DOI: 10.1177/2055116921999595.
- LEAL, R. O.; PEREIRA, H.; CARTAXEIRO, C.; DELGADO, E.; PELETEIRO, M. C.; FONSECA, I. P. Granulomatous rhinitis secondary to feline leishmaniosis: report of an unusual presentation and therapeutic complications. **Journal of Feline Medicine and Surgery Open Reports**, v.4, n.2, p.1-7, 2018. DOI: 10.1177/2055116918811374.

LIBERT, C.; RAVEL, C.; PRATLONG, F.; LAMI, P.; DEREURE, J.; KECK, N. Leishmania infantum infection in two captive Barbary lions (*Panthera leo leo*). **Journal of Zoo and Wildlife Medicine**, v.43, n.3, p.685-688, 2012. DOI: **10.1638/2012-0056.1**.

LOPES-NETO, B. E. L.; LIMA, A. L.; SANTOS, G. J. L.; GONÇALVES, L. D.; MAIA, F. M. M.; FREITAS, J. C. C.; NUNES-PINHEIRO, D. C. S. Avaliação da resposta inflamatória em cães naturalmente infectados por *Leishmania infantum*. **Revista Brasileira de Higiene e Sanidade Animal**, v.9, n.4, p.645-656, 2015. DOI: **10.5935/1981-2965.20150058**.

NAPOLI, E.; BENEDETTO, G.; FAZIO, C.; RUSSA, F.; GAGLIO, G.; BRIANTI, E. Clinical case of feline leishmaniosis: therapeutic approach and long-term follow-up. **Veterinary Sciences**, v.9, n.8, p.400-411, 2022. DOI: **10.3390/vetsci9080400**.

PAULA, B. F. de; RODRIGUES, G. de S.; COSTA, J. A. de S.; SOUZA, E. F. de; COSTA, A. C. M. de S. F. da. Tratamento da esporotricose após cirurgia gástrica em felinos: revisão de literatura. **Revista Ibero-Americana de Humanidades, Ciências e Educação**, v.9, n.6, p.425-441, 2023. DOI: **10.51891/rease.v9i6.10167**

PENNISI, M. G.; CARDOS, L.; BANETH, G.; BOURDEAU, P.; KOUTINAS, A.; MIRÓ, G.; OLIVA, G.; SOLANO-GALLEGO, L. LeishVet update and recommendations on feline leishmaniosis. **Parasites & Vectors**, v.8, n.302, p.1-18, 2015. DOI: **10.1186/s13071-015-0909-z**.

PENNISI, M. G.; PERSISCHETTI, M. F. Feline leishmaniosis: Is the cat a small dog? **Veterinary Parasitology**, v. 251, p. 131-137, 2018. DOI: **10.1016/j.vetpar.2018.01.012**.

PINEDA, C.; TEJERO, E. A.; MORALES, M. C.; LORENZO, S. B.; NIETO, L. C. G.; GARCIA, P.; MORENO, J. M. M.; ORTIZ,

M. E. R.; LOPEZ, I. Treatment of canine leishmaniasis with marbofloxacin in dogs with renal disease. **PLoS ONE**, v.12, n.10, p.1-17, 2017. DOI: **10.1371/journal.pone.0185981**.

SCHÄFER, I.; SCHMIDT, A.; GRÄBER, F.; SCHIESZLER, A.; LELLBACH, G. A.; LOESENBECK, G.; GENTIL, M.; MÜLLER, E.; NAUCKE, T. J. Feline leishmaniosis with focus on ocular manifestation: a case report. **Parasites & Vectors**, v.16, n.1, p.161-171, 2023. DOI: **10.1186/s13071-023-05741-0**.

SILVA, F. S.; CUNHA, S.C.S.; BAPTISTA, A.R.S.; BAPTISTA, V.S.; SILVA, K.V.G.C.; COELHO, T.F.Q.; FERREIRA, A.M.R. Miltefosine Administration in Cats with Refractory Sporotrichosis. **Acta Scientiae Veterinariae**, v.46, n.1, p.1-7, 2018. DOI: **10.22456/1679-9216.83639**.

SOARES, C. S. A.; DUARTE, S. C.; SOUSA, S. R. What do we know about feline leishmaniosis? **Journal of Feline Medicine and Surgery**, v.18, n.6, p.435-442, 2015. DOI: **10.1177/1098612X15589358**.

TIOZZO, A. A.; MASSERDOTTI, C.; BECATTINI, L.; OTTAIANO, P.; FERRARI, F.; TAMBORINI, A. Long-term follow-up of a case of feline leishmaniosis treated with a combination of allopurinol and meglumine antimoniate. **The Canadian Veterinary Journal**, v.64, n.3, p.239-244, 2023.

TORRES, M. G.; LÓPEZ, M. C.; TASKER, S.; LAPPIN, M. R.; BRUGUÉ, C. B.; ROURA, X. Review and statistical analysis of clinical management of feline leishmaniosis caused by *Leishmania infantum*. **Parasites & Vectors**, v.15, n.1, p.253, 2022. DOI: **10.1186/s13071-022-05369-6**.

TRAVI, B. L.; MIRÓ, G. Use of domperidone in canine visceral leishmaniasis: gaps in veterinary knowledge and epidemiological implications. **Memórias do Instituto Oswaldo Cruz**, v.113, n.11, p.1-4, 2018. DOI: 10.1590/0074-02760180301.

PEREIRA, A.; MAIA, C. Leishmania infection in cats and feline leishmaniosis: An updated review with a proposal of a diagnosis algorithm and prevention guidelines. **Current Research in Parasitology & Vector-Borne Diseases**, v.1, n.1, p.1-21, 2021. DOI: 10.1016/j.crpvbd.2021.100035.



[Este é um artigo publicado em acesso aberto \(Open Access\) sob a licença Creative Commons Attribution, que permite uso, distribuição e reprodução em qualquer meio, sem restrições desde que o trabalho original seja corretamente citado.](#)