



## A clinical and diagnostic approach of a dog with hyperadrenocorticism and hypothyroidism related: Case report

*Abordagem Clínico-Diagnóstico de um cão com Hiperadrenocorticismo Associado ao Hipotireoidismo: Relato de Caso*

**Glícia Meneses Costa<sup>1</sup>, Steffi Lima Araujo<sup>2</sup>, Francisco Antônio Félix Xavier Júnior<sup>3</sup>,  
Ângela Rocha de Lima<sup>4</sup>, Daniel de Araújo Viana<sup>5</sup>, Janaina Serra Azul Monteiro  
Evangelista<sup>6</sup>.**

1. Programa de Pós-graduação em Ciências Veterinárias, Universidade Estadual do Ceará, UECE – Médica Veterinária. E-mail: gliciamcosta@hotmail.com
2. Faculdade de Veterinária, Universidade Estadual do Ceará, UECE – Graduanda. E-mail: steffi.araujo@hotmail.com
3. Faculdade de Veterinária, Universidade Estadual do Ceará, UECE – Médico Veterinário. E-mail: juniorberith@gmail.com
4. Faculdade de Veterinária, Universidade Estadual do Ceará, UECE – Médico Veterinário. E-mail: viana\_daniel@yahoo.com.br
5. Clínica Veterinária Cães e Gatos - Médica Veterinária. E-mail: clinicaveterinariacaesegatos@bol.com.br
6. Laboratório de Morfologia Experimental Comparada do Programa de Pós-graduação em Ciências Veterinárias, Universidade Estadual do Ceará, UECE – Médica Veterinária. E-mail: janainaserrazul@gmail.com

**Abstract** ; Dermatological diseases are the most frequent causes of veterinary appointments in the world. Hyperadrenocorticism is caused by the chronic excess of circulating endogenous or exogenous glucocorticoids, resulting in a set of physical and biochemical changes. Hypothyroidism is caused by imbalance in any part of the hypothalamic-pituitary-thyroid axis. These endocrinopathies cause bilaterally symmetrical alopecia and other skin disorders. The aim of this study was a dog, male, Yorkshire breed, which the presence of chronic dermatological alterations was reported. In the physical examination, bilaterally symmetrical alopecia, bilateral otitis and pyoderma were observed. Complementary laboratory tests required were: microbiology, parasitology, serum biochemistry and histopathology of the skin. Among other findings, the histopathological findings showed alterations suggestive of hormonal

dermatosis: oto keratotic hyperkeratosis, sebaceous glands atrophy and hair follicles. The definitive diagnosis was obtained by combination of the complementary tests and clinical signs presented for the patient. So, it is clear the importance of using complementary laboratory tests such as histopathology and serum biochemistry combined with a correct clinical approach.

**Keywords:** hormonal dermatosis, histopathology, endocrinopathies.

**Resumo:** As doenças dermatológicas são as causas mais frequente de consultas veterinárias no mundo. O hiperadrenocorticismo é causado pelo excesso crônico de glicocorticoides endógenos ou exógenos circulante, tendo como resultado um conjunto de alterações físicas e bioquímicas. O hipotireoidismo é causado pelo desequilíbrio em qualquer parte do eixo hipotálamo-hipófise-tireoide. Essas endocrinopatias causam alopecia bilateral simétrica e outras alterações cutâneas. O objeto de estudo foi um cão, macho, raça Yorkshire, no qual foi relatada a presença de alterações dermatológicas crônicas. No exame físico foi observado alopecia simétrica bilateral, otite bilateral e piodermite. Foram solicitados exames complementares de microbiologia, parasitologia, bioquímica sérica e histopatológico de pele. Dentre outros achados, o histopatológico apresentou alterações sugestivas de dermatose hormonal: hiperqueratose otoqueratótica, atrofia de glândulas sebáceas e folículos pilosos. O diagnóstico definitivo se deu com a combinação dos exames complementares e dos sinais clínicos apresentados pelo paciente. Fica clara a importância da utilização de exames complementares laboratoriais como o histopatológico e bioquímica sérica combinados com uma abordagem clínica correta.

**Palavras-chaves:** dermatose hormonal, histopatológico, endocrinopatias.

---

Autor para correspondência: E-mail: \* juniorberith@gmail.com

Recebido em 12.07.2016. Aceito em 28,12.2016

<http://dx.doi.org/10.5935/1981-2965.20160063>

## Introduction

Dermatological diseases are the most frequent cause of veterinary appointment in the world. Among the appointments accomplished in hospitals and veterinary clinics, 20 to 75% of cases are related to

dermatological disorders, which 8.6% are caused by endocrinopathies (CARDOSO et al., 2011; SCOTT & PARADIS, 1990; TEXEIRA et al., 2009). Hyperadrenocorticism (HAC) and hypothyroidism are among the most

frequently diagnosed endocrinopathies in middle-aged dogs and they cause dermatological problems in animals affected by these diseases. HAC is caused by chronic excess of circulating endogenous or exogenous glucocorticoids, resulting in a set of physical and biochemical changes (NELSON & COUTO, 2009).

HAC usually has an insidious and progressive onset. Most owners interpret signs as a consequence of their pet's advanced age (HERRTAGE, 2004). Polyuria / polydipsia is the most common initial systemic signal and they may precede typical cutaneous changes of the disease in about 6 to 12 months (SCARAMPELLA, 2011). Other frequent characteristics are polyphagia and distended abdomen. This last characteristic is due to fat distribution in various areas of the abdomen, hepatomegaly, increased urinary bladder and weakness of the abdominal muscles (NELSON & COUTO, 2009).

The dermatological manifestations of canine HAC include alopecia, usually symmetrical and bilateral, head and extremities are usually spared. The hair left remains opaque and dry. Dog's skin affected by HAC is thin, hypotonic, fragile, dry and little elastic. Phlebitis, comedones, cutaneous hyperpigmentation, pyoderma,

dermal atrophy, secondary demodicosis and seborrhoea are observed (DOERR et al., 2013; GRECO, 2007; SCARAMPELLA, 2011).

The diagnosis of HAC is based on clinical suspicion according to the history and clinical examination. For confirmation, routine laboratory tests are necessary, such as a hemogram, serum biochemistry, complete urinalysis and urine culture. Screening tests are essential components in the diagnosis of HAC, however, these should not be used alone but used to confirm the clinical suspicion of the veterinarian. Abdominal ultrasonography, histopathological skin biopsy, computed tomography and magnetic resonance imaging are also tests that aid in the confirmation of the diagnosis (ETTINGER & FELDMAN, 2010; NELSON & COUTO, 2009).

Hypothyroidism is caused by imbalance in any part of the hypothalamic-pituitary-thyroid axis (MOONEY, 2011). It is classified as primary, secondary or tertiary of natural or iatrogenic occurrence (FERGUNSON, 2007; SCOTT-MONCRIEFF, 2007). The main forms of primary hypothyroidism are autoimmune lymphocytic thyroiditis and idiopathic thyroid atrophy, both of them are very

common, about 50% of hypothyroidism cases are caused by lymphocytic thyroiditis (ETTINGER & FELDMAN, 2010; KEMPPAINEN & CLARK, 1994).

The most common clinical signs of hypothyroidism are those related to decreased metabolism and skin disorders. Many dogs are prone to gain weight and some degree of mental retardation, lethargy, intolerance, or exercise aversion (NELSON & COUTO, 2009; SCOTT-MONCRIEFF, 2007).

Thyroid hormones are extremely important in maintaining cutaneous function, they play a regulatory role in epidermal differentiation, in part because of its effects on keratinocytes (DOSHI, BLYUMIN & KIMBALL, 2008). The main characteristic is non-inflammatory, non-itchy bilaterally symmetric alopecia, and tragic face associated with other cutaneous alterations (MÜNTENER et al., 2012; NELSON & COUTO, 2009; SCOTT et al., 2001).

The most frequently measured thyroid hormones for the diagnosis of hypothyroidism are total T4 (TT4), total T3 (TT3) and free T4 (fT4) (ETTINGER and FELDMAN, 2010). Thus, the present study aimed to describe the clinical-diagnostic approach of a case on hyperadrenocorticism associated with hypothyroidism in a dog.

## **Materials and methods**

A canine, male, Yorkshire breed, named Theo, weighting 3.3 kg, aged 11 years was attended on April 30, 2016 at the Clínica Veterinária Cães & Gatos in Fortaleza city, Ceará state.

### ***Anamnesis***

In the anamnesis the owner reported that the dog had a persistent skin dysfunction for at least two years. The animal was submitted to different treatments by veterinarians, but the treatment only had an effect at the beginning, but at the end of the treatment the skin problem came back again. Drugs used for treatment were shampoo based on chlorhexidine, benzoyl peroxide, miconazole and use of hypoallergenic feed.

### ***Physical exam***

On physical examination, the animal was alert, 38 °C of body temperature, normohydrated and normocorated mucosa. Auscultation showed normal parameters. Abdominal distention was also observed. In the skin, bilaterally symmetrical alopecia was observed, dry and rough fur, presence of papules and pustules and bilateral otitis. Serum biochemistry (free T4 and basal cortisol), skin and fur scrapings for ectoparasite and fungal research, bacterial culture with antimicrobial susceptibility test

(TSA), dermatophyte and yeast culture and cutaneous biopsy of skin lesions were requested.

The treatment initially instituted was cefovecin at a dose of 8 mg / kg as a single subcutaneous injection. After hyperadrenocorticism and hypothyroidism diagnosed, treatment instituted was levothyroxine at 11 mg / kg, BID, orally for 60 days for hypothyroidism and trilostane at a dose of 3 mg / kg, SID, orally for hyperadrenocorticism. Treatment monitoring was performed three months after initiation of treatment. Then free T4, serum chemistry and basal cortisol tests were repeated.

### **Results and discussions**

In the present case report it is observed that the dog presented in his anamnesis bilaterally alopecia, due to the opaque and dry, comedones and cutaneous hyperpigmentation, these findings corroborate with Scarampella (2011), which affirm that dogs with HAC present the same symptomatology. It should be noted that bilaterally alopecia and hyperpigmentation are also classic cutaneous manifestations of other endocrinopathies (SCARAMPELLA, 2011; MÜNTENER, 2012).

Physical examination revealed bilateral otitis and dermatitis with crusts. In the bacterial culture examination the growth

of *Staphylococcus* coagulase negative sensitive to the following antibiotics: amoxicillin + clavulanic acid, azithromycin, cefepime, cephalexin, clindamycin, chloramphenicol, gentamicin, neomycin, rifampicin, sulfa + trimethoprim, tetracycline and tobramycin. On the other hand, the complementary tests performed for ectoparasites and fungi, dermatophyte fungi and yeast culture of the present study obtained negative results. These findings corroborate with data from the literature that canine hypothyroidism predisposes to recurrent bacterial infections in the skin, with pyoderma reported in 10-23% of cases. Secondary infections may also be observed in dogs with hyperadrenocorticism (SCARAMPELLA, 2011; SCOTT-MONCRIEFF, 2007).

In the serum biochemistry, the value of fT4 was below the reference values (0.64 ng / dL, reference values: 0.80 - 2.00 ng / dL) and baseline cortisol values presented a value of Reference values (85, 90 ng / ml, reference values: 10.0-40.0 ng / dL).

The diagnosis of this case was performed with baseline cortisol measurement proving to be quite high concomitantly with presence of clinical signs compatible with HAC, Kooistra & Galac (2010) observed that the most

effective way to obtain a definitive diagnosis is to perform tests that assess pituitary-adrenal axis function. Low-dose dexamethasone suppression test (0.01 mg / kg) is the screening test most used, collecting blood samples before and after 4 and 8 hours of drug administration.

Obtaining the definitive diagnosis of canine hypothyroidism is based on the history and clinical signs that are suggestive of the disease, and the results of the laboratory tests (CASTILLO, 2011). FT4 is the circulating thyroxine fraction that did not conjugate to plasma proteins (usually 0.1% of TT4). Therefore, the measurement of fT4 provides an analysis of the hormone concentration available to the tissues. There is a high correlation between the clinical status of the animal and the amount of free T4 (DIXON, 2001; FERGUSON, 2007).

The histopathological sections of the skin show irregular acanthosis with areas of orthokeratosis and parakeratosis that reaches the light of hair follicles forming keratin plugs (comedones) (figure 01-B and C). Atrophy of hair follicles and sebaceous glands (figure 01-A). The dermis is the site of discrete fibroplasia and inflammatory infiltrate distributed mainly in the superficial dermis, consisting of lymphocytes, plasma cells and macrophages, which also

sometimes involve hair follicles (figure 01-D).

These histopathological findings are compatible with that described for hormonal dermatosis, as described by Scott et al. (2001). Hair follicle atrophy was observed in the study accomplished by Tsujio et al. (2008), where he studied thyroidectomized rats. Müntener et al. (2012) reported that sebaceous glands atrophy and the presence of comedones are histopathological findings of dogs affected by non-inflammatory alopecia, among them hyperadrenocorticism and hypothyroidism.

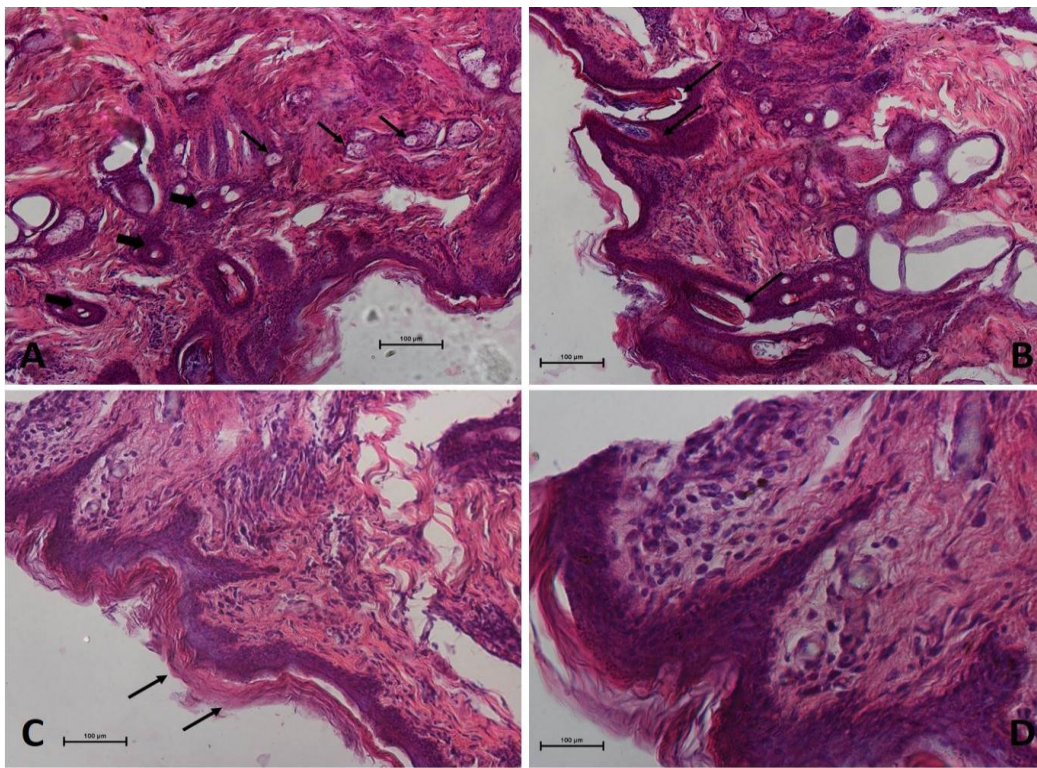
The presence of classic clinical signs of symmetric bilateral alopecia and dermatological alterations combined with the results of the complementary tests of parasitology, microbiology, serum biochemistry and cutaneous biopsy culminated in the diagnosis of canine hyperadrenocorticism associated with hypothyroidism.

The treatment of hypothyroidism aims to normalize the hypothalamic-pituitary-thyroid axis and circulating T4 levels. For this, it is recommended the use of synthetic levothyroxine (NELSON & COUTO, 2009; CASTILLO, 2011). The recommended dose of levothyroxine is 11-22 µg / kg, administered once or twice daily, ideally to

start with the lowest dose and then gradually increase the dosage to reach the desired concentration, the dose used in dog patient of 11 mg / kg (CASTILLO, 2011; TVARIJONAVICIUTE, 2013).

Trilostane is a competitive inhibitor of 3- $\beta$ -hydroxysteroid dehydrogenase, enzyme that mediates the conversion of

pregnenolone to progesterone, consequently of its end products (cortisol, aldosterone and androstenedione) in adrenals. The recommended dose is 3-10 mg / kg / SID, in this case the option chosen was to start treatment with the lowest dose (GRECO, 2007).



**Figure 01:** Photomicrographs of the dog's skin biopsy. (A) Photomicrograph shows hair follicle (thick arrow) and endocrine glands (fine arrows) atrophy at 100X magnification. (B) Photomicrograph shows areas of ortho and parakeratotic hyperkeratosis that reaches the light of hair follicles forming keratin plugs at 200X magnification. (C) Photomicrography points hyperkeratosis (arrows) at 200X magnification. (D) Photomicrography points a dermis with discrete fibroplasia and inflammatory infiltrate distributed mainly in the main dermis, consisting of lymphocytes, plasma cells and macrophages.

Due to the presence of secondary infection, treatment with cefovecin at the dose of 3 mg / kg was instituted, this antibiotic was chosen because of the results of the antimicrobial sensitivity test and the convenience of being used in a single dose.

### Conclusion

It can be concluded that canine hyperadrenocorticism may be associated with hypothyroidism, and the diagnosis of these diseases is difficult due to similarities in dermatological clinical signs present in both pathologies. Therefore, it is necessary to use a detailed clinical-diagnostic approach using devices such as biochemical, histopathological and parasitological tests.

### References

1. CARDOSO, M.J.L.; MACHADO, L.H.A.; MELUSSI, M.; ZAMARIAN, T.P.; CARNIELLI, C.M.; JUNIOR, J.C.M.F. Dermatopatias em cães: revisão de 257 casos. **Archives of Veterinary Science**, Curitiba, v.16, n.2, p.66 -74, 2011.
2. CASTILLO, V. Hipotiroidismo Canino. **Veterinary Focus**, Boulogne, v.21, n.1, p.2 - 8, 2011.
3. DIXON, R. Recent developments in the diagnosis of canine hypothyroidism. **In Practice**, United Kingdom, n.23, v.6, p.328 - 334, 2001.
4. DOERR, K.A.; OUTERBRIDGE, C.A.; WHITE, S.D.; KASS, P.H.; SHIRAKI, R.; LAM, A.T. ; AFFOLTER, V. K. Calcinosis cutis in dogs: histopathological and clinical analysis of 46 cases. **Veterinary Dermatology**, United Kingdom, v.24, p. 355 – 379, 2013.
5. DOSHI, D.N.; BLYUMIN, M.L.; KIMBALL, A.B. Cutaneous manifestations of thyroid

disease. **Clinics in Dermatology**, Philadelphia, v. 26, p.283 – 287, 2008.

6. ETTINGER, S.J.; FELDMAN, E.C. Hypothyroidism and Hyperadrenocorticism. Textbook of Veterinary Internal Medicine. Seventh Edition. Elsevier Saunders. 2010.

7. FELDMAN, E. & NELSON, R. Hypothyroidism. In E. Feldman, & R. Nelson, Canine and Feline Endocrinology and Reproduction. 3<sup>a</sup> Edição. Missouri: Saunders. 2004.

8. FERGUSON, D.C. Testing for Hypothyroidism in Dogs. **Veterinary Clinics Small Animal Practice**, v.37, p.647 – 669, 2007.

9. FERGUNSON, D. & PETERSON, M. Serum free and total iodothyronine concentrations in dogs with hyperadrenocorticism. **American Journal of Veterinary Research**, Schaumburg, v.53, p.1636 - 1640, 1992.

10. FRANK, LA; DONNELL, RL; KANIA, SA. Oestrogen Receptor Evaluation in Pomeranian Dogs with Hair Cycle Arrest (Alopecia X) on Melatonin Supplementation. **Journal Compilation European Society of Veterinary Dermatology**, Bristol, v. 17, p. 252 - 258, 2006.

11. GRECO, D.S. Hyperadrenocorticism Associated with Sex Steroid Excess. **Clinical Techniques in Small Animal Practice**, v.22, p.12 - 17, 2007.

12. HERRTAGE, ME. Canine Hyperadrenocorticism. In: Mooney, CT e Peterson, ME. Eds. BSAVA Manual of Canine and Feline Endocrinology. 3<sup>a</sup> ed. Gloucester, England: British Small Animal Veterinary Association.150-170, 2004.

13. KEMPPAINEN, R. J. & BEHREND, E. N. **Veterinary Clinics of North America Small Animal Practice**, Maryland Heights, v. 31, n. 5, 2001.



- 14.KEMPPAINEN, R.J. & CLARK, T.P. Etiopathogenesis of canine hypothyroidism. **Veterinary Clinics of North America Small Animal Practice**, Maryland Heights, v. 3, n. 24, p. 467 – 476, 1994.
- 15.KOOISTRA, H.S. & GALAC, S. Recent Advances in the Diagnosis of Cushing's Syndrome in Dogs. **Veterinary Clinics of North America Small Animal Practice**, Maryland Heights, v.40, p. 259 – 267, 2010.
- 16.MOONEY, C.T & PETERSON, M.E. Investigation of simmetrical alopecia in dogs; Canine Hypothyroidism and Canine Hyperadrenocorticism. **BSAVA Manual of Canine and Feline Endocrinology**. Third Edition. 2004.
- 17.MÜNTENER, T., SCHUEPBACH-REGULA, G., FRANL, L., RÜFENACHT, S. & WELLE, M. M. Canine noninflammatory alopecia: a comprehensive evaluation of common and distinguishing histological characteristics. **Dermatology Veterinary**, United Kigdom, v.23, p. 206 – 244, 2012.
- 18.NELSON, R.W & COUTO, C.G. Disorders of Thyroid Gland and Disorders of the Adrenal Gland. **Small Animal Internal Medicine**. Fourth Edition. 2009.
- 19.SCARAMPELLA, F. Alopecia Endócrina no Cão. **Veterinary Focus**, Boulogne, v.21, n.1, p. 40 - 46, 2011.
20. SCOTT-MONCRIEFF, J. C. Clinical Signs and Concurrent Diseases of Hypothyroidism in Dogs and Cats. **Veterinary Clinics Small Animal Practice**, v.37, p. 709 – 722, 2007.
- 21.SCOTT, D.W. & PARADIS, M.A survey of canine and feline skin disorders seen in a university practice: Small Animal Clinic, University of Montréal, Saint-Hyacinthe, Québec (1987-1988). **Canadian Veterinary Journal**, Ottawa, v.31, n.12, p.830 - 835, 1990.
- 22.SCOTT, D.W.; MILLER, D.H.; GRIFFIN, C.E. Muller & Kirk – Small animal dermatology. 6th.ed. Philadelphia: Saunders, 2001.
- 23.TEXEIRA, A.S.; MENDOÇA, M.L.; GONÇALVES, V.D.; RODRIGUES, L.F.; SILVA, A.C.R; RIBEIRO, R.G. Estudo retrospectivo das dermatopatias mais prevalentes em cães e gatos na cidade de Rio Verde - GO, Brasil.V Jornada e IV Mostra Científica da Faculdade de Medicina Veterinária 24 e 25 de novembro de 2009.
- 24.TEXEIRA, R.D.S. Hipotireoidismo em cães dermatopatas: aspectos clínico-laboratoriais comparados ao exame histopatológico da pele. (Dissertação de Mestrado) - Universidade Federal Rural do Rio de Janeiro, RJ, 2008.
- 25.TVARIJONAVICIUTE, A., JAILLARDON, L., CERÓN, J.J., SILIART, B. Effects of thyroxin therapy on different analytes related to obesity and inflammation in dogs with hypothyroidism. **The Veterinary Journal**, United Kingdom v. 196, p.71 – 75, 2013.



